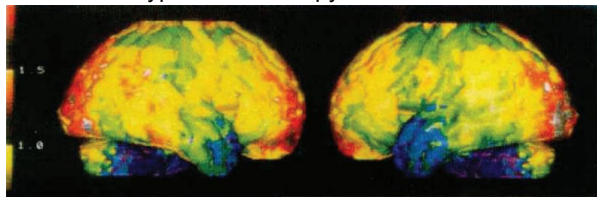
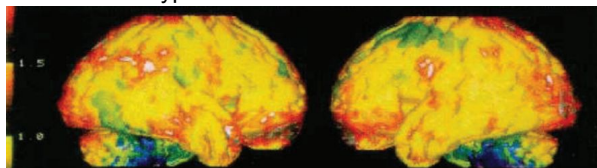


Clinical Study: Mild Hyperbarics for Impaired Brain Function

Before Mild Hyperbaric Therapy



After 10 Mild Hyperbaric Treatments



Yellow = Normal Green = Less blood Blue & Violet = Severe lack of blood

Methods

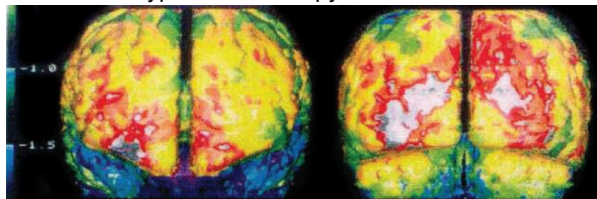
Each patient was given a series of 10 hyperbaric treatments: one hour per day for five consecutive days for two weeks. To objectively test the effects of the hyperbaric sessions, SPECT scans were taken of each patient's brain before and after the series of treatments.

SPECT Imaging

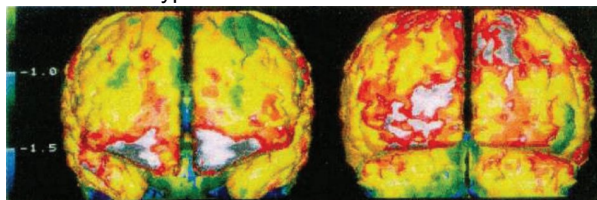
SPECT stands for Single Photon Emission Computed Tomography. A scan is performed by injecting the patient with a radioactive substance that travels through the brain and distributes itself according to the circulatory system. The patient's brain is then scanned and a computer creates a three dimensional color image that illustrates the blood flow into all areas of the brain. SPECT imaging helped us by identifying the parts of the brain that are dormant due to a lack of oxygen.

A normal, healthy adult brain should read primarily yellow on a SPECT scan. Green is indicative of less blood flow and oxygen. Blue and violet represent significantly reduced blood flow in the brain.

Before Mild Hyperbaric Therapy



After 10 Mild Hyperbaric Treatments

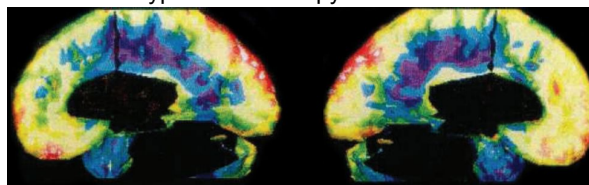


Yellow = Normal Green = Less blood Blue & Violet = Severe lack of blood

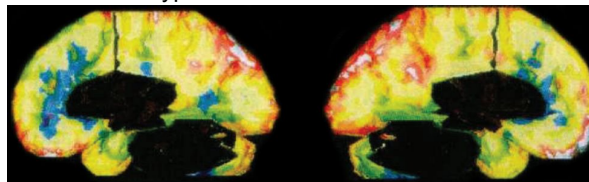
Introduction

Dr. Gunnar Heuser, a toxic exposure specialist, documented results of a series of hyperbaric treatments on 9 patients suffering from Impaired Brain Function. The purpose was to study the effects of 1.3 ATA of hyperbaric therapy on those patients. His patients included individuals who suffered from impairment to brain function such as memory and balance due to years of exposure to a variety of chemicals, pesticides and solvents. Some patients had developed attention deficit disorder and may well have been experiencing disabling effects that altered their quality of life. It is important to note that MRI scans confirmed that there was no cell death in those patients, only loss of function.

Before Mild Hyperbaric Therapy



After 10 Mild Hyperbaric Treatments



Yellow = Normal Green = Less blood Blue & Violet = Severe lack of blood

Results

Every one of the patients who participated in the study showed improvement after only 10 treatments. Reporting fewer problems with short term memory, balance, headaches, and other symptoms of poor circulation in the brain. The SPECT scans objectively confirmed an increase in blood flow and oxygen to effected areas of the brain such as the temporal lobe, the part of the brain where short term memory is located. The improvements in the temporal lobe seen in the SPECT scans were verified when the patient regained his short term memory.

Discussion

The benefits of treating toxic exposure patients with Hyperbaric Therapy appear to be very positive. Initial results indicate that Hyperbaric Therapy has a demonstrable and positive effect on some symptoms such as short term memory loss and balance. This study and additional research will add to our understanding of the exciting possibilities of Hyperbaric Therapy.

"we are happy to say our patients subjectively improved but the SPECT scans show they also objectively improved with increased blood flow to the temporal lobe and other areas of the brain."

- Dr. Gunnar Heuser, MD, PhD, FACP